

Research Article

HEPATOPROTECTIVE ACTIVITY OF SAPONIN FRACTION OF OYONG SEED FLESH AND ITS COMBINATION AGAINST CCl₄-INDUCED CHRONIC LIVER DAMAGE IN MALE WISTAR RAT

Heni Rachmawati, R. Leony Y. Hartiadi, Irda Fidrianny, I Ketut Adnyana

School of Pharmacy,
Institut Teknologi
Bandung, Jl. Ganesa 10,
Bandung 40132,
Indonesia

Submitted: 05-01-2013

Revised: 15-03-2013

Accepted: 25-05-2013

*Corresponding author
Heni Rachmawati

Email :
hrachma@yahoo.com

ABSTRACT

Saponin fraction of seed flesh of Oyong (*Luffaacutangula* [L.] Roxb) has been investigated to have a hepatoprotective activity in rats with fibrotic chronic liver damage. This research was conducted to evaluate whether saponin fraction of Oyongseed flesh has a hepatoprotective activity in CCl₄-induced acute liver damage. Hepatoprotective activity was determined by measuring the activity of liver enzymes (SGOT, SGPT, LDH), total nitrite/nitrate level, liver index and liver histology. Saponin fraction of Oyong flesh seeds 10mg/kg BW and meniran extract 400mg/kg BW alone showed hepatoprotective activity. Administration of saponin fraction 10mg/kg BW decreased SGPT and LDH significantly over untreated group. Group given meniran extract at dose of 200mg/kg BW showed decreased on LDH, while at dose of 400mg/kg BW decreased SGPT, SGOT, and LDH significantly. Hystological observation revealed any improvement in liver morphology especially after treated with saponin fraction 10mg/kg BW and meniran extract at dose of 400mg/kg BW. However, all groups treated with combination of saponin and meniran did not show improvement both at biochemical parameter and liver histology. In conclusion, saponin extract with dose of 10mg/kg BW and meniran extract at dose of 400mg/kg BW showed hepatoprotector activity. In contrast, combination of both did not show any hepatoprotective effect and it was suspected that they have antagonist effects.

Key words: hepatoprotective, CCl₄-induced liver fibrosis, *Luffaacutangula*, *Phyllanthus niruri*

INTRODUCTION

The liver is vital organ responsible for the metabolism, detoxification, and secretory functions of the body. Increasing both acute and chronic liver disorders caused by viruses, alcohol, drugs, and other hepatotoxic materials remains a health problem not only in developing countries but also in developed countries.

Several studies have reported that a group of triterpenoid compounds, either free triterpenoids and bound to one or more glucose molecules and form saponins are proven to have hepatoprotector activity (Adnyana *et al.*, 2000; Yoshikawa *et al.*, 2003). The studies have also proven that *Luffaacutangula* plant shows the same activity. Based on its biochemical parameters, organ index and histological studies of the *Luffaacutangula* saponin fraction, it is indicated that its seed flesh (known as oyong) has a hepatoprotector

activity in rat model of liver fibrosis (Pratiwi, 2008; Anny, 2008). However, there was no study evaluating the hepatoprotective activity of oyong seed flesh in a rat model of acute liver damage.

Phyllanthus niruri, also known as meniran, is a plant commonly used in multi herbal preparations addressed to treat liver disorders (Amelia, 2006; Harish and Shivanandappa, 2006). The hepatoprotective effect of meniran has been demonstrated in numerous studies and oftenly is associated with its antioxidant activity (Sarkat *et al.*, 2005; Chatterjee and Sil, 2006; Harish and Shivanandappa, 2006; Sabir and Rocha, 2008). The active compounds responsible for the hepatoprotective activity of meniran include phyllantin, hypophyllantine and triacontanol (Shamasundar *et al.*, 1985). In multiherbal preparation, each component interacts with each other resulting in better effect than that of individual components (Yan

et al., 2009). Therefore, this study also evaluated the hepatoprotective activity of Oyong saponin fraction combined with meniran. This combination is expected to have a better hepatoprotective activity than the Oyong saponin fraction alone.

MATERIAL AND METHODS

Oyong (*Luffa acutangula* [L.] Roxb.) seed flesh; Silymarin; meniran herb extract meniran (PT Jamu Borobudur); CMC-Na; distilled water; carbon tetrachloride; olive oil; 96% ethanol; *n*-butanol; *n*-hexane; Liebermann-Burchard reagent; Steasny reagent; sodium hydroxide; hydrochloric acid; SGPT (*Analyticon*), SGOT (*Analyticon*), and LDH (*Analyticon*) reagent, *seribu* fish, absolute alcohol, 70% alcohol, xylol, albumin, entelan, Bouin solution (consists of saturated picric acid, a solution of formaldehyde, acetic acid glacial of 15:5:1 composition), paraffin, haematoksin-eosin, chloroform, sodium chloride, vanadium trichloride (Sigma), aqua bidestilata, phosphoric acid, sulfanilamide, *N*-1-naftiletilediamin (nedd), zinc sulfate, KNO₃.

Testing animal

Wistar male rats, 2-3 months of age with average weight of 200-240g were obtained from D Wistar farm and Pusat Ilmu Hayati ITB. Prior to testing, animals were first adapted for one week in the animal laboratory. Animals were weighed daily and their behaviour was recorded. Animals were considered healthy and could be used in the experiments if their behavior did not show any symptoms of illness and their weight did not decrease.

Oyong seed flesh fractionation

Total of 510g Oyong flesh seeds that had been dried and powdered were extracted with 1.1L of 96% ethanol using reflux method. Herbs refluxed 3 times, each for 3h. Extract then filtered and dried with rotating vacuum evaporator to obtain concentrated ethanol extracts. Concentrated ethanol extracts then fractionated by liquid-liquid extraction using *n*-hexane and *n*-butanol. Fractions were collected and evaporated to obtain concentrated fractions. Extracts and fractions obtained were

determined for its total saponin content using fish index method.

Fish index determination

The extract was brewed to obtain water infusion with concentration of 10%w/v. The obtained infusion then diluted with water to obtain infusion with concentration of 1%, 0.5%, 0.25%, 0.1%, 0.05%w/v. Three or five *seribu* fishes were then put into each container containing 1%, 0.5%, 0.25%, 0.1%, and 0.05% saponin. The number of dead fish was counted after one hour.

Study hepatoprotective activity *in vivo*

Male Wistar rats were divided into 12 groups, consisting of normal group (A, was given 0.5% CMC-Na solution orally for 6 days); control group (B, was given 0.5% CMC-Na solution orally for 6 days and 50% CCl₄ solution in olive oil, 2mL/kg BW via intra peritoneal injection on day four); the comparison group (C, was given silymarin 100mg/kg BW for 6 days and CCl₄ solution ip on day four); and 8 treated groups (each group were given saponin fraction 10mg/kg BW orally – group D, saponin fraction 20mg/kg BW orally – group E, seed flesh extract 10mg/kg BW orally – group F, seed flesh extract 20mg/kg body weight, meniran extract 200mg/kg BW orally – group G, meniran extract 400mg/kg BW orally – group H, combination of saponin fractions 10mg/kg BW and meniran extract 200mg/kg BW orally – group I, the combination of saponin fraction 5mg/kg BW and meniran extract 200mg/kg BW orally – group J, a combination of saponin fractions 10mg/kg BW and meniran extract 400mg/kg BW orally – group K, for 6 days and given CCl₄ solution via intra peritoneal injection on day four). At day 7, the animals were sacrificed then the blood and livers were collected prior to analysis. Hepatoprotective activity was determined by measuring the activity of liver enzymes (SGOT, SGPT, LDH), total nitrite/nitrate level, liver index and liver histology. Liver index was calculated using formula as followed:

$$\text{Liver index} = \frac{\text{liver weight (gram)}}{\text{rat body weight (gram)}} \times 100 \%$$

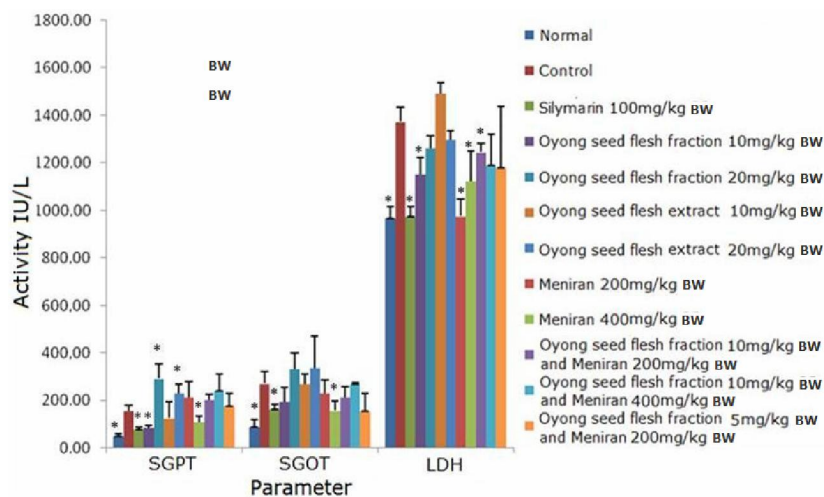


Figure 1. SGPT, SGOT and LDH levels in normal group, control group, comparison group and treated groups.

Tabel I. Fish Index of different substances

Sample	Fish Index
Ethanolic extract	3030
Water extract	1000
<i>n</i> -butanol fraction	7407
<i>n</i> -heksan fraction	-

Tabel II. Histomorphology scoring in all groups

Group	Level of damage
Normal	0
control	4
<i>Silymarin</i>	1
Oyong fraction 10mg/kg bw	2
Oyong fraction 20mg/kg bw	3
Oyong extract 10mg/kg bw	3
Oyong extract 20mg/kg bw	4
Meniran extract 200mg/kg bw	4
Meniran extract 400mg/kg bw	3
Oyong fraction 10mg/kg bw + meniran extract 200mg/kg bw	4
Oyong fraction 10mg/kg bw + meniran extract 400mg/kg bw	4
Oyong fraction 5mg/kg bw + meniran extract 200mg/kg bw	4

Study on the hepatic enzymes activity

The hepatic enzymes activity was tested from blood samples. Test animals were sacrificed then their blood was drawn and collected in Eppendorf tubes. The blood was then centrifuged at 12,000rpm for 6min. The activity of SGPT , SGOT, and LDH enzymes were measured from serum samples.

Determination of total nitrate/nitrite level

Total nitrate/nitrite was determined from serum samples. Serum was diluted twice with aqua bidestilata and deproteinated by adding of 1:21 volume of zinc sulfate 300g/L to obtain a final concentration of 15g/L. After the samples were centrifuged at 10,000rpm for 5min, 200mL of supernatant was mixed

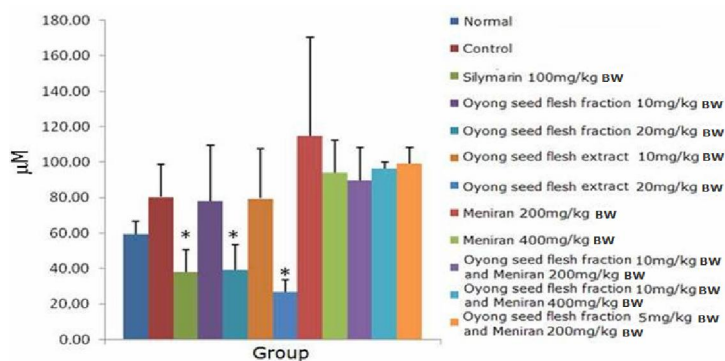


Figure 2. Total Nitrite/Nitrate levels in normal group, control group, comparison group and treated groups. Values showed on the figure are mean \pm SD
*:significantly different compared to control group (CCl₄) (p< 0.05), N= 3-5

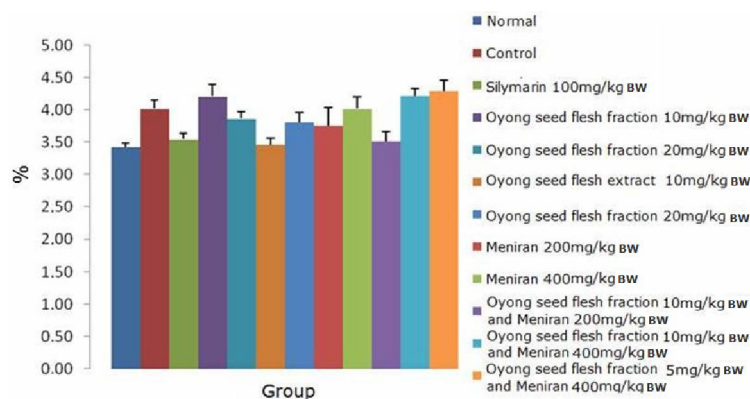


Figure 3. Liver index of normal group, control group, comparing group and treated groups. Values showed on the figure are mean \pm SD
*:significantly different compared to control group (CCl₄) (p< 0.05), N= 3-5

with 200mL of vanadium trichloride (8mg/mL in 1N HCl) and immediately followed by the addition of Griess reagent (0.1% Nedd, 1% to 5% sulfanilamide phosphate 1:1). The mixture was incubated at 37°C for 30min and the absorbance was measured at wavelength of 546 nm. A calibration curve was made by using KNO₃.

Histological analysis

Liver of test animals were taken and kept in Bouin fixation solution, dehydrated in graded alcohol solutions, cleared in xylol and then embedded in paraffin prior to further treatment, to obtain slices with a thickness

of 5µm. The slices then placed on the glass object then stained using Hematoxylin-eosin solution.

Statistical analysis

All data are expressed as mean values \pm SD. Statistical analysis was performed using independent t-test with p <0.05 was considered as significantly different.

RESULTS AND DISCUSSION

Saponins are compounds consisted of aglycone and glycone. Aglycone of saponins can be either steroids or triterpenoids. Sugar residues bonded through OH group (usually

the C-3-OH) of the aglycone or through a single OH group and a carbonyl group (Wagner, 1996). Based on this structure, saponin contains polar residue due to the influence of the sugar group and semi-polar or non-polar residues because of its aglycone group.

Fractionation process of Oyong seed flesh was done as previous studies (Pratiwi, 2008; Anny, 2008). The yield of extract obtained was 9.16%(w/w). Fractionation carried out by liquid-liquid extraction using *n*-hexane and *n*-butanol. Extraction using *n*-hexane was aimed to obtain non-polar components in the ethanol extract. The process then followed by liquid-liquid extraction using *n*-butanol, to obtain polar compounds, including the glycosides of saponin.

Most saponins have hemolytic properties and are toxic to cold-blooded animals, especially fish (Bruneton, 1999). Therefore, the concentration or potency of saponin in a material can be determined by testing its toxicity to fish. *n*-Butanol fraction had highest fish index (Table I). This suggests that the saponin is most abundant in *n*-butanol fraction. Saponin fraction was then used to determine the hepatoprotective activity rat model.

Hepatoprotective activity of a compound was indicated by its ability to reduce the liver damage or to maintain a normal liver function. In this study, CCl₄ was used to induce liver damage. It is one of the most potent hepatotoxins and able to induce acute liver damage. Liver changes caused by CCl₄ are mimicking liver disease in humans, including acute hepatitis (Yadav *et al.*, 2008; Zhu *et al.*; 2010).

CCl₄ toxicity depends on the formation of free radicals, which cuts through the carbon-chlorine bond to generate trichloromethyl radicals (\bullet CCl₃). This radical reacts rapidly with oxygen to form peroxy trichloromethyl radicals (\bullet CCl₃O₂). Carbon-chlorine bond cleavage that occurs in the endoplasmic reticulum is mediated by cytochrome P450 monooxygenase (Plaa and Charbonneau, 2001). Free radicals derived from CCl₄ can initiate the auto catalytic peroxidation of lipid by attacking the methylene bridge of unsaturated fatty acids side chain from the lipid microsomal, binds irreversibly to

hepatic protein, and disturbs the balance of Ca²⁺homeostasis, which end up leading to cell death (Plaa and Charbonneau, 2001; Kalantari 2009). Hepatotoxins also stimulate the sympathetic nervous system to release hormones. This reduces hepatic blood flow due to vasoconstriction, thus inducing centrilobularhypoxia, degeneration, necrosis and causing fat mobilization on a large scale from the peripheral (Andrews, 1963).

In liver damage, the level of enzymes such as Serum Glutamate Pyruvate Transaminase (SGPT), Serum Glutamate Oxaloacetate Transaminase (SGOT) and Lactate Dehydrogenase (LDH) will increase significantly. Impaired transport function of hepatocytes as a result of liver damage leading to leakage of these enzymes from cells is due to changes in permeability. As a result, the enzymes levels in the hepatocytes will decline and enzymes level in serum will be elevated (Yadav *et al.*, 2008).

CCl₄ administration to animals was causing an increment of Serum Glutamate Pyruvate Transaminase (SGPT) ($p=0.000$); Serum Glutamate Oxaloacetate Transaminase (SGOT) ($p=0.006$); and Lactate Dehydrogenase LDH ($p = 0.001$); significantly compared to the normal group. This indicated that hepatocellular damage has occurred. Silymarin decreased the activity of SGPT ($p = 0.004$), SGOT ($p=0.004$), and LDH ($p = 0.001$) significantly in comparison to controls. This suggests that silymarin has potent hepatoprotective activity.

Fraction of oyong seed flesh of 10mg/kg BW showed similar activity as silymarin indicated by decreasing of SGOT ($p = 0.006$) and LDH ($p=0.015$) levels significantly compared to that of control group. In addition, the SGOT level also decreased, but was not significantly different. Fraction of oyong seed flesh of a larger dose (20mg/kg BW) did not show hepatoprotective activity.

In addition, the SGOT level was also decreased, but was not significant. Larger dose administration of oyong seed flesh fraction (20mg/kg BW) did not show hepatoprotective activity. This result suggests that the optimum dose of Oyong seed flesh fraction dose of 10mg/kg BW. SGOT, SGPT and LDH levels

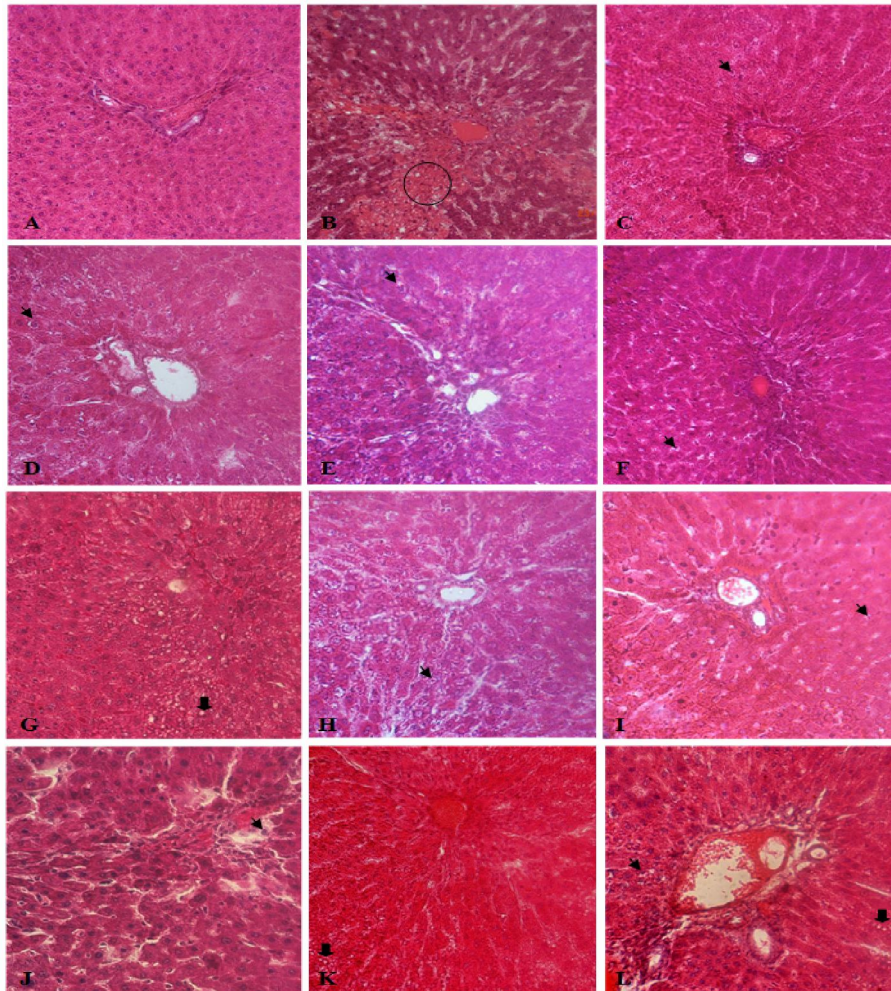


Figure 4. Histological presentation of the liver. A. Normal group. B. Control group. C. Group treated with Silymarin. D. Treated group given oyong seed flesh fraction 10mg/kg BW. E. Treated group given oyong seed flesh fraction 20mg/kg BW. F. Treated group given oyong seed flesh extract 10mg/kg BW. G. Treated group given oyong seed flesh extract 20mg/kg BW. H. Treated group given meniran extract 200mg/kg BW. I. Treated group given meniran extract 400g/kg BW. J. Treated group given the combination of oyong seed flesh fraction 10 mg/kg BW and meniran extract 200mg/kg BW. K. Treated group given the combination of oyong seed flesh fraction 10mg/kg BW and meniran extract 400mg/kg BW. L. Treated group given the combination of oyong seed flesh fraction 5mg/kg BW and meniran extract 200mg/kg BW (400x magnification).

The circle signs indicate sentrilobular necrosis and hemorrhage. The arrow indicates the degeneration of hepatocytes, while thick arrows indicate vacuolation

of groups given Oyong seed flesh fraction of 10mg/kg BW and 20mg/kg BW showed no amelioration as compared to the control group. Hepatoprotective activity differences between Oyong seed flesh fractions of 1mg/kg BW and

oyong seed flesh extracts of 10mg/kg BW and 20mg/kg BW (based on the fish index) seems to be influenced by saponin content.

Treated group of meniran extract of 200mg/kg BW showed a significant decrease

on LDH enzyme activity ($p=0.002$) compared to control group. Meanwhile, meniran extract administration of 400mg/kg BW decreased SGPT ($p=0.04$), SGOT ($p=0.034$) and LDH ($p=0.038$) enzyme activity significantly. This suggests that the hepatoprotective activity of meniran was dose dependent.

The group given combination of Oyong seed flesh fraction of 10mg/kg BW and meniran extract 200mg/kg BW showed reduction on LDH activity ($p=0.037$) significantly. SGOT levels also decreased, but was not statistically significant compared to the control group. The combination of oyong seed flesh fraction (5mg/kg BW) and meniran extract (200mg/kg BW) provides a better activity than that of combination with higher concentration, although it was not statistically significant. Combination of Oyong seed flesh fraction and meniran extract has low activating compared to Oyong seed flesh of 10mg/kg BW or meniran extract of 400mg/kg BW alone. The decrease in activity is supposed due to antagonist pharmacological mechanism between Oyong seed flesh and meniran extract.

In the inflamed liver administration upon of CCl_4 , the iNOS expression is increasing and it produces NO in a large quantities (Li and Billiar, 1999). NO is a very unstable compound with a very short half-life making difficult to do a direct measurements of NO (Moshage *et al.*, 1995; Li and Billiar, 1999). Instead, nitrate and nitrite, the end metabolites of NO, has been used as an indirect marker to determine the formation of NO in vivo (Ghasemi *et al.*, 2007). In the circulation, nitrite rapidly is oxidized to nitrate by oxyhemoglobin, therefore the determination of nitrite alone as a marker of NO levels become meaningless (Moshage *et al.*, 1995; Moshage 1997). Therefore, vanadium trichloride is used as a reducing agent (Moshage *et al.*, 1995; Miranda *et al.*, 2001; Ghasemi *et al.*, 2007). Total nitrite level in the sample was determined based on Griess' diazotation method. The control group had the same nitrite/nitrate value to that of normal group. This indicated that the increment of NO level was caused by CCl_4 administration which causing a damage to the liver through the formation of radicals. Therefore, the body produces NO which

provides a protective effect by reducing the level of oxidative stress (Li and Billiar, 1999). Silymarin administration of 100mg/kg BW significantly suppresses the increased total nitrite/nitrate caused by CCl_4 administration ($p=0.031$).

This result was in line with the treated groups' index liver values that were significantly different compared to controls. Silymarin suppressed the inflammatory process occurring in the liver. Treated group given Oyong seed flesh fraction of 10mg/kg BW and meniran extract of 400mg/kg BW had better SGOT, SGPT, LDH and histological profile, but did not change the total nitrite / nitrate. It suggested that both fractions saponin 10mg/kg BW and meniran 400mg/kg BW does not affect NO formation pathways. The treated group showing significant difference to the control was the group given saponin fraction of 20mg/kg BW ($p=0.02$) and 20mg extract /kg BW ($p=0.003$). However, by analyzing subjects' liver enzymes functions and histological profiles both treatment did not show hepatoprotective effects. Determination of total nitrite/nitrate level did not specifically show the condition of the liver and might be affected by other parts of the body.

However, because the total nitrate/nitrite data was not supported by other parameters, it is concluded that the administration of saponin fraction (20mg/kg BW) and extract (20mg/kg BW) shows no hepatoprotective effect.

CCl_4 administration causes liver swelling (hepatomegaly), as indicated by the increment of liver index in treated group significantly compared to that of the normal group ($p=0.002$). Group given silymarin of 100mg/kg BW significantly has a lower liver index compared to control group ($p=0.032$). This suggests a hepatoprotective effect of silymarin. Group given oyong seed flesh fraction of 10mg/kg BW and meniran extract 400mg/kg BW showed no significant difference compared to control group. These results show that those two treatments did not give a strong hepatoprotective activities compared to silymarin. Treated group given oyong seed flesh extract of 10mg/kg BW and the combination of seed flesh fraction (10mg/kg BW) and

meniran extract (200mg/kg BW) have an index close to normal liver. The lack of supporting parameter to hepatoprotective effect implied that low value of liver index might due to pathological event in the liver.

Figure 4. Histological presentation of the liver. A. Normal group B. Control group. C. Group treated with Silymarin. D. Treated group given oyong seed flesh fraction 10mg/kg BW. E. Treated group given oyong seed flesh fraction 20mg/kg BW. F. Treated group given oyong seed flesh extract 10mg/kg body weight. G. Treated group given oyong seed flesh extract 20mg/kg BW. H. Treated group given meniran extract 200mg/kg BW. I. Treated group given meniran extract 400g/kg BW. J. Treated group given the combination of oyong seed flesh fraction 10mg/kg BW and meniran extract 200mg/kg body weight. K. Treated group given the combination of oyong seed flesh fraction 10mg/kg BW and meniran extract 400mg/kg BW. L. Treated group given the combination of oyong seed flesh fraction 5mg/kg BW and meniran extract 200mg/kg BW (400x magnification). The circle signs indicate sentrilobular necrosis and hemorrhage. The arrow indicates the degeneration of hepatocytes, while thick arrows indicate vacuolation

There is a different on liver histological presentation between normal and control groups. Normal group showed normal liver architectural structure, i.e. radial and compact hepatocytes. Meanwhile, in the control group the hepatocytes arrangement seemed to be tenuous and there were signs of centrilobular necrosis accompanied by severe bleeding. Group treated with silymarin showed microscopic morphology of the liver that is almost resembling the normal group, although a minor hepatocytes degeneration was still observed. This result is also in line with other parameters that support the hepatoprotective effect of silymarin. In the group given Oyong seed flesh fractions of 10mg/kg BW, the liver morphology was better than control although minor hepatocytes degeneration was observed. Mean while the treated group given Oyong seed flesh fraction of 20mg/kg BW showed less effective. In this group, the composition of hepatocytes

remained tenuous. In addition, severe hepatocytes degeneration was found. Treated group with Oyong seed flesh extract of 10mg/kg BW showed better liver appearance than group given 20mg/kg BW showing severe vacuolation). In group given meniran 200mg/kg BW, hepatocytes degenerative signs, considerable amount of vacuolation and a tenuous arrangement of hepatocytes were found.

Meanwhile, the group given meniran extract of 400mg/kg BW showed better liver morphology, as also confirmed in table II. This suggests that the hepatoprotective activity of 400mg/kg BW meniran is better than 200mg/kg BW. Liver histology of all three groups given combination of oyong seed flesh and meniran showed a tenuous arrangement of hepatocytes, hepatocytes degeneration and vacuolation. This reinforces that the hepatoprotective activity of those combinations were not effective. As previously discussed the declining effect is suggested due to antagonism effect of oyong seed flesh fraction on meniran extract.

CONCLUSION

Fraction of oyong seed flesh with dose of 10mg/kg BW given for six consecutive days to the rat is proved to show a hepatoprotective activity. Increasing the dose up to 20mg/kg BW even resulted in no hepatoprotective activity. The active compound responsible for this hepatoprotective effect is saponin. A strong hepatoprotective effect also shown in this study is observed on meniran extract as a single dose of 400mg/kg BW. However, when meniran extract was combined with fraction of oyong seed flesh the hepatoprotective effect was diminished, presumably any antagonism between those two components.

ACKNOWLEDGEMENT

The authors are thankful to School of Pharmacy ITB for providing facilities.

REFERENCES

- Adnyana, I. K., Y. Tezuka, A.H. Banskota, dan S. Kadot, 2000, Hepatoprotective Constituents of the Seeds of *Combretumquadrangulare*, *Biol Pharm Bull*, **23**(11), 328-332.

- Amelia, D., 2006, Efek Hepatoprotektif Sediaan Campuran Ekstrak *Andrographispaniculata*, *Phyllanthusniruri*, & *Phaleriamacrocarpa* pada Mencit Balblc, Sekolah Farmasi ITB, Bandung, 1-25.
- Anny, N., 2008, Pengembangan Model Hewan Tikus Fibrosis Hati dan Uji Aktivitas Hepatoprotektif Fraksi Saponin Daging Biji Oyong (*Luffaacutangula* [L.]Roxb) pada Tikus Fibrosis Hati, Sekolah Farmasi ITB, Bandung, 1-26.
- Bruneton, J., 1999, *Pharmacognosy, Phytochemistry, Medicinal Plants*, 2nd, Intercept Ltd., New York, 672-683.
- Chatterjee, Mary dan Sil, P. C., 2006, Hepatoprotective Effect of Aqueous Extract of *Phyllanthusniruri* on Nimesulide-induced Oxidative Stress *in vivo*, *Indian J Biochem Biophys.*, 43(5), 299-305
- Ditjen POM, Depkes RI, 2000, *Parameter Standar Umum Ekstrak Tumbuhan Obat*, Departemen Kesehatan RI, Jakarta, 13-17.
- Ghasemi, Asghar, Hedayati, dan Biabani, H. 2007, Protein Precipitation Methods Evaluated for Determination of Serum Nitric Oxide End Products by the Griess Reaction, *J Med Scie Res.*, 2, 29-32.
- Harish, T. dan Shivanandappa, T., 2006, Antioxidant Activity and Hepatoprotective Potential of *Phyllanthusniruri*, *Food Chem.*, 95(2), 180-185.
- K.V. Shamasundar, B. Singh, R.S. Thakur, A. Hussain, Y. Kisodan H. Hikino, 1985, Antihepatoprotective Principles of *Phyllanthusniruri* Herbs, *J Ethnopharmacol.*, 14(1), 41-44.
- Li, Jianrong dan Billiar, Timothy R., 1999, Nitric Oxide. IV. Determinants of nitric oxide protection and toxicity in liver., *Am. J. Physiol.*, 39, 1069-1073.
- Miranda, K.M., Espey, M.G., dan Wink D.A., 2001, A Rapid, Simple Spectrophotometric Method for Simultaneous Detection of Nitrate and Nitrite, *NITRIC OXIDE: Biology and Chemistry*, 5(1), 62-71.
- Moshage, Han, B. Kok, J.R. Huizenga, dan P.L.M. Jansen, 1995, Nitrite and Nitrate Determination in Plasma: A Critical Evaluation, *Clin. Chem.*, 41(6), 892-896.
- Plaa, G. L. dan Charbonneau, M., 2001, Detection and Evaluation of Chemically Induced Liver Injury, dalam: *Principles and Method of Toxicology*, Hayes, A. Wallace (Ed.), edisi 4, Taylor & Francis, Philadelphia, 1145-1178.
- Pratiwi, E, 2008, Pengembangan Metode Fraksinasi Saponin dan Pengujian Aktivitas Hepatoprotektif Fraksi Saponin dari Daging Biji Oyong (*Luffa acutangula* (L.) Roxb) pada Tikus Wistar Jantan, Sekolah Farmasi ITB, Bandung, 1-25.
- Sabir, S.M. dan Rocha, J. B. T., 2008, Water-extractable Phytochemicals from *Phyllanthus niruri* Exhibit Distinct *in vitro* Antioxidant and *in vivo* Hepatoprotective Activity Against Paracetamol-induced Liver Damage in Mice, *Food Chem.*, 111(4), 845-851.
- Sarkar, M. K., K. Sarkar, R. Bhattacharjee, M. Chatterjee, P. C. Sil, 2005, Curative Role of The Aqueous Extract of The Herb, *Phyllanthusniruri*, Against Nimesulide Induced Oxidative Stress in Murine Liver, *Biomed Res.*, 16(3), 171-176.
- Yadav, N.P., A. Pal, K. Shanker, D.U. Bawankule, A. K. Gupta, M.P. Dorakar, dan S.P.S Khanuja, 2008, Synergistic Effect of Silymarin Standarized Extract of *Phyllanthusamarusagaints* CCl₄-induced Hepatotoxicity in *Rattusnorvegicus*, *Phytomedicine*, 15, 1053-1061.
- Yan, F., Q. Zhanga, L. Jiaoa, T. Hana, H. Zhanga, L. Qina, dan R. Khalid, 2009, Synergistic hepatoprotective effect of *Schisandradignans* with *Astragalus* polysaccharides on chronic liver injury in rats, *Phytomedicine*, 16(9), 805-813.
- Yoshikawa, M., T. Morikawa., Y. Kashima, K. Ninomiya, dan H. Matsuda, 2003, Structures of New Dammarane Triterpene Saponins from the Flower Buds of *Panaxnotoginseng* and Hepatoprotective Effects of Principal Ginseng Saponin, *J.Nat. Prod.*, 66, 922-927.